



Thermal Imaging Report

Zippo My Lady



*Thermal Imaging completed by
a Certified Thermographer
Authorized with the EquineIR™
Network.*



*Interpretative results
completed by Licensed
Veterinarians in contract with
Integrated Equine Infrared.*



Equine Resources Imaging Services
303-3 Rampton St. Morden, MB R6M 1W7

PH: 204-332-1333

WEB: www.equineresources.webs.com
EMAIL: equine_resources@yahoo.ca



Phone: 204-332-1333
Email: equine_resources@yahoo.ca
Web: www.equineresources.webs.com
www.equineir.com

PATIENT: Zippo My Lady

THERMOGRAPHY DATE: September 5, 2013

IMAGING TIME: 7:50pm

September 14, 2013

Ginger Peterka
135660 60th St NE
Pisek, ND 58273

Dear Ginger Peterka:

EquineIR was recently requested to perform a full body thermal imaging scan of: **Zippo My Lady**

The following photo report was completed by your EquineIR™ Certified Thermographer and all interpretative results were channeled through interpretir.com and subsequently formulated and input by a licensed veterinary team member with Integrated Equine Infrared.

The interpretation is intended to aid your state-licensed veterinarian in providing a diagnostic or treatment protocol. All follow-up testing and treatments should be conducted and administered by your primary veterinarian. The interpretation provided is based solely on the conditions at the time of survey and the thermal images included in this report. Thermography is a diagnostic tool that measures heat emitted from the surface of the patient. The thermal imaging camera converts infrared energy into a visible image. Emitted heat is related to circulation; as such, the thermal camera can help detect areas of inflammation as well as decreased circulation. Thermal symmetry is key, so you compare one anatomic area with the same area on the other side. The EquineIR™ report is prepared in this manner. It should be understood that correct patient preparation and environment are vital to a successful survey. Your EquineIR™ technician is also a Certified Infrared Thermographer and has been trained in the proper use and the proven techniques of thermal imaging as it is used with horses. There are however certain situations which may reduce the quality of the survey including the improper preparation of the horse prior to technician's arrival. The interpreting veterinarians who review the imagery base their findings and recommendations on information provided, so it is critical that proper care be taken in the preparation process to ensure success.

Thermal imaging is a physiologic modality and should not be relied upon as the sole diagnostic tool. A complete clinical examination by your state-licensed veterinarian is always recommended for the best diagnosis and follow-up treatment. This Report is not a definitive diagnosis of any illness or disease. It is intended for use only by licensed veterinary professionals to evaluate patient health, diagnose medical conditions, and provide treatment. It is not to be used by individuals for self-diagnosis or self-evaluation, nor for the diagnosis or evaluation of other non-qualified personnel. This report does not replace, nor is intended to replace a complete clinical evaluation by your state-licensed veterinarian. Under no circumstances will EquineIR™, Integrated Equine Infrared or its affiliates be held responsible for illness, injury, or death to the patient as a result of the information contained herein. This report does not replace, nor is intended to replace a complete clinical evaluation.

Your EquineIR™ Technician looks forward to working with you in the future. If you would like to set up an ongoing maintenance imaging program for your horse(s), we can arrange this at discounted rates along with multiple horse discounts. Please call our office with any questions as we would love to assist you in your success.

Sincerely,

Connie Friesen

Connie Friesen, *Certified Infrared Thermographer*
Equine Resources



Phone: 204-332-1333
 Email: equine_resources@yahoo.ca
 Web: www.equineir.com
 www.equineir.com

PATIENT: Zippo My Lady

THERMOGRAPHY DATE: September 5, 2013

IMAGING TIME: 7:50pm

EQUINE CLIENT INFORMATION

CLIENT NAME: Ginger Peterka
MAILING ADDRESS: 13566 60th St NE, Pisek, ND 58273
CLIENT EMAIL: gpeterka@hotmail.com
CLIENT PHONE: 701-331-0361

HORSE AGE: 15
HORSE BREED: Quarter Horse
HORSE PRIMARY USE: Barrel Racing

SURVEY INFORMATION

THERMOGRAPHER: Connie Friese
INFRARED CERTIFICATION #: 9036
INFRARED CAMERA MODEL: Flir T420 **CAMERA SERIAL NUMBER:** 62101463
NUMBER OF THERMAL IMAGES SUBMITTED: 30

WEATHER: Humid
APPROXIMATE TEMPERATURE: 80 °F
IMAGING LOCATION: Barn

EXERCISED PRIOR: Yes **HOW LONG:** 15 minutes **WHEN:** 6:20pm (horse sweated up easily)
TYPE OF EXERCISE: Lunged

BOOTS OR WRAPS ON HORSE? No

FLYSPRAY OR LINIMENTS APPLIED WITHIN 24 HOURS: Yes

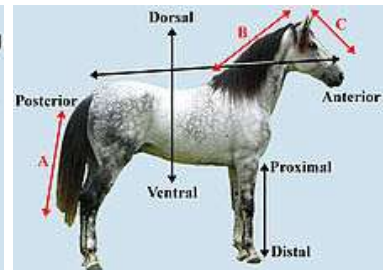
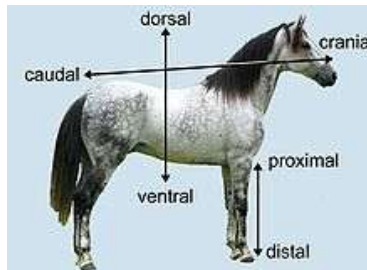
REASON FOR SCAN or HISTORY RECEIVED: Client purchased horse in February of this year. She had marks on both sides from prior saddle sore issues. Have had Chiro/Massage several times for maintenance. Horse has been showing tenderness to her left front shoulder area recently and crossfire's at the lope. Previous owner has always ran her in shoes, currently she is barefoot. Obvious shortstriding and lameness observed during movement, with suspected scratches on hind pasterns. Horse was difficult to image due to unwillingness to stand, and very bothered by flies. Two imaging sessions took place this evening with about 40 minutes in between at which time fly spray was applied. Owner would like to evaluate any underlying issues that could be causing her soreness/lameness.

INTERPRETATION INFORMATION (Completed by Veterinarian)

INTERPRETATION TYPE: Full Enhanced Survey

DATE OF INTERPRETATION: 9/13/2013

REVIEWING VETERINARIAN: Dr. Debra K Tibbitts

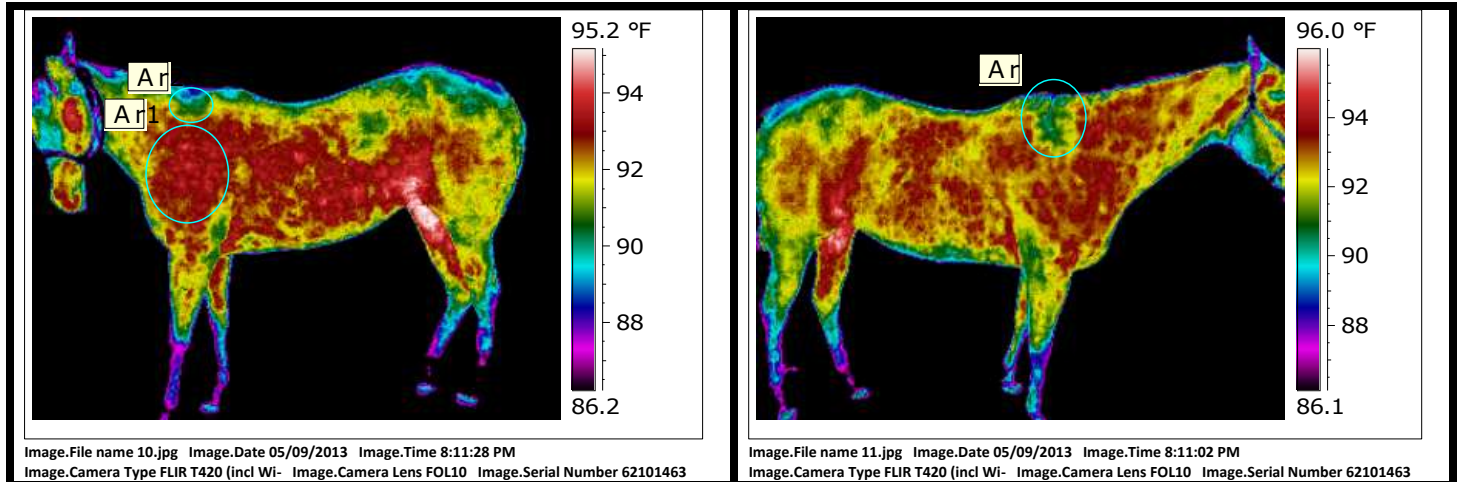




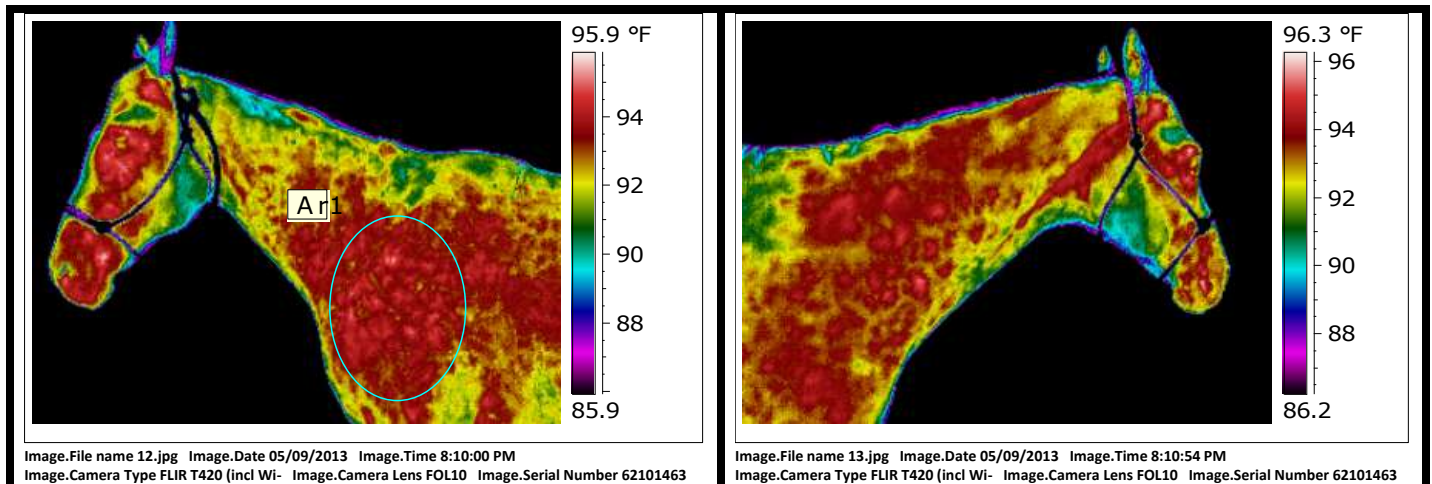
PATIENT: Zippo My Lady

THERMOGRAPHY DATE: September 5, 2013

IMAGING TIME: 7:50pm



Areas of coolness seen in the withers that correspond with scarring from old saddle sores. Asymmetry seen in the shoulder area with the left shoulder having more heat than the right. This may be due to primary inflammation, muscular strain, scapular fixation, feet imbalances causing uneven limb loading or there may be off-loading of other limb. Palpation, motion palpation and gait analysis recommended.



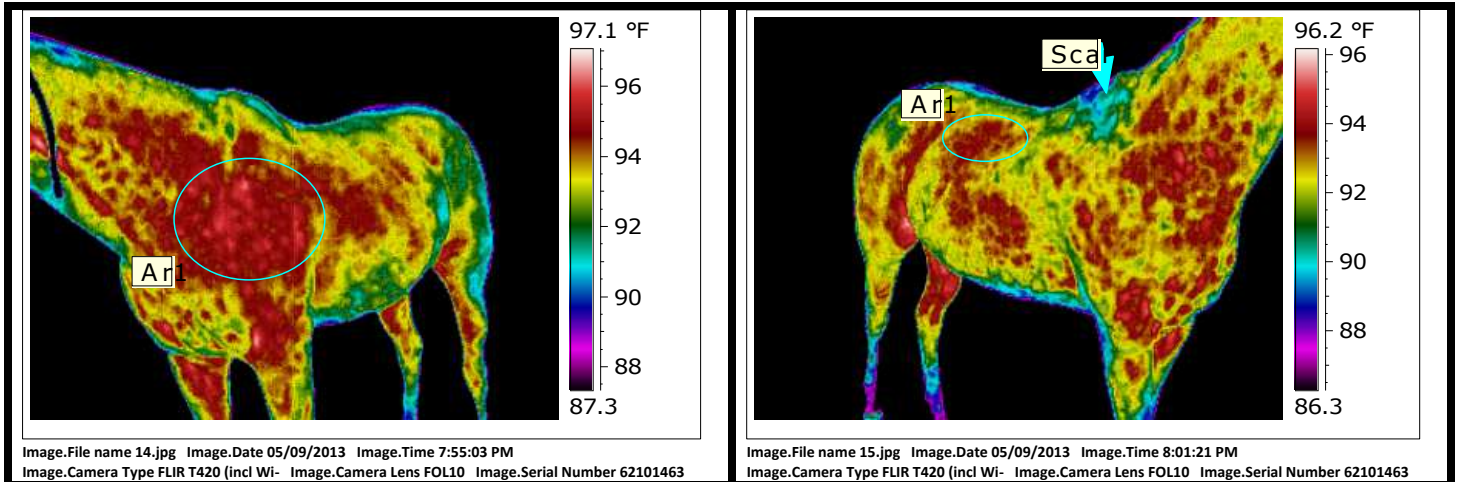
Asymmetry in shoulders. See comments above.



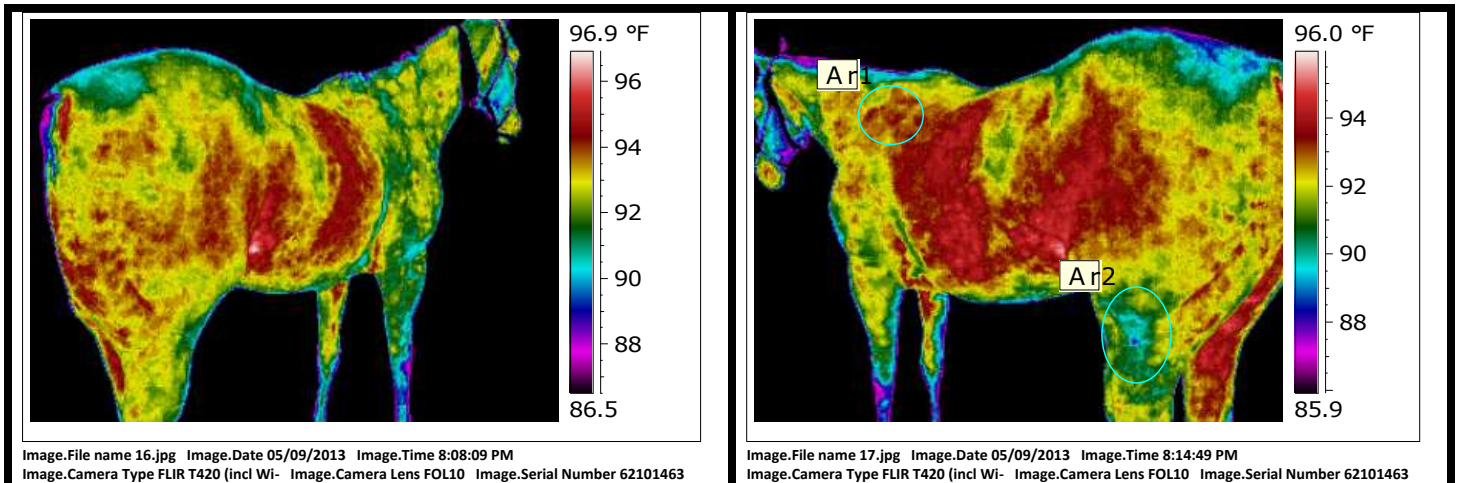
PATIENT: Zippo My Lady

THERMOGRAPHY DATE: September 5, 2013

IMAGING TIME: 7:50pm



Asymmetry again seen in the shoulders. See comments page 4, images 10/11. Increased heat right paraspinal muscles – palpation recommended checking for muscular inflammation and chiropractic rotations/fixations.



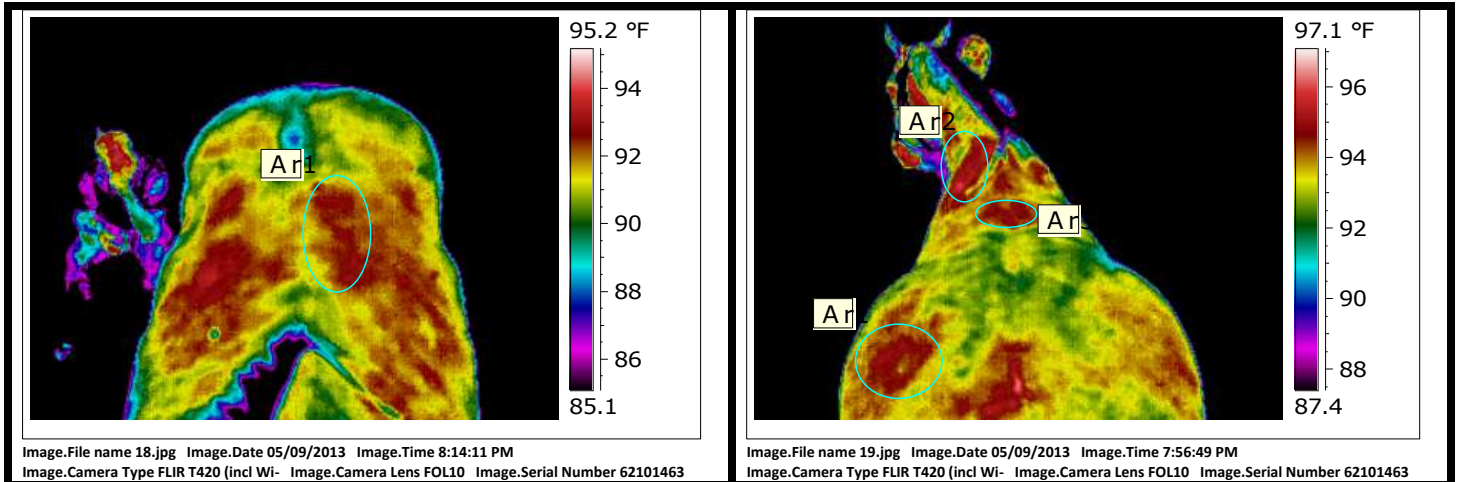
Increased heat left shoulder/wither area possible musculoskeletal strain, chiropractic lesions or saddle fit issue. Palpation recommended. Left lateral stifle has cool area which may be due moisture artifact or could be scarring. Palpation recommended.



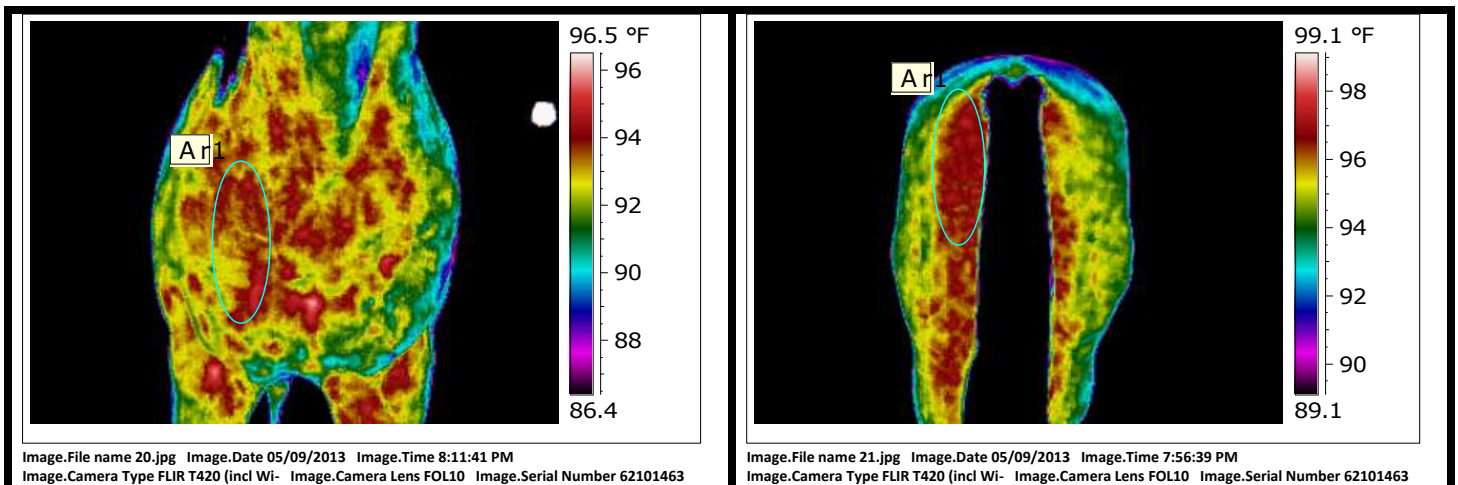
PATIENT: Zippo My Lady

THERMOGRAPHY DATE: September 5, 2013

IMAGING TIME: 7:50pm



Increased heat left shoulder (see previous comments page 4, image 10). Asymmetry in gluteal muscles/hip with heat greater in the left hind which may be artifact, uneven limb loading or inflammation. Palpation including motion palpation recommended. Increased heat thoracolumbar spine and paraspinal musculature – palpation and motion palpation recommended.



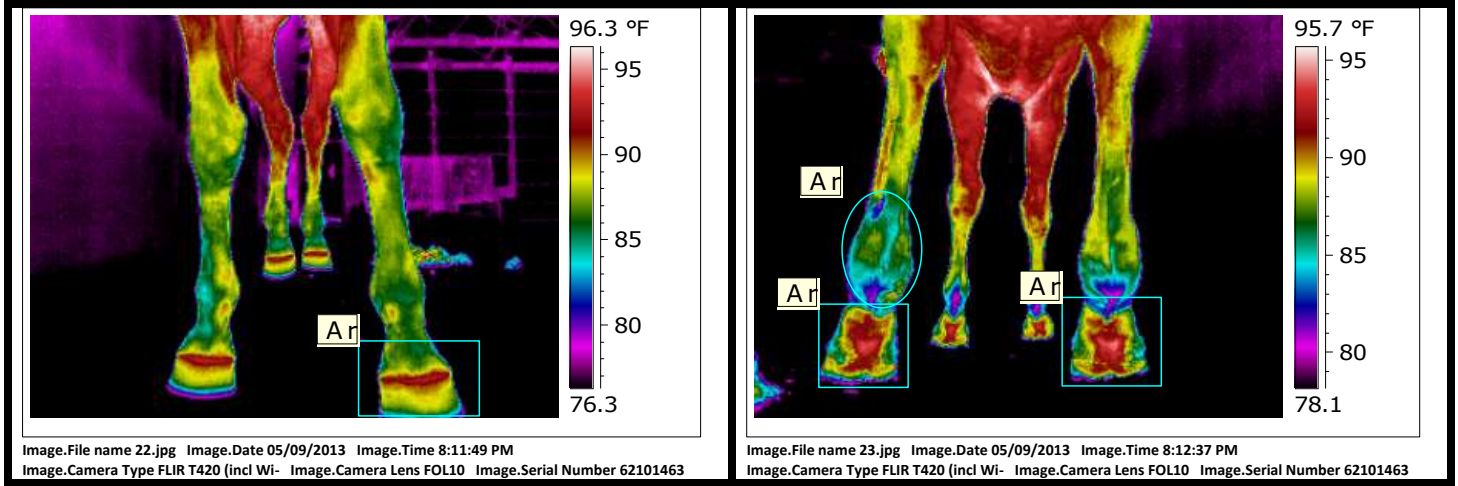
Slight asymmetry in the chest with heat heater on the right. Palpation recommended checking for inflammation/strain but may be due to off-loading of other limb. Asymmetry in the semitendinosus muscle with heat greater on the left. There may be muscular inflammation/strain or uneven limb loading present. Palpation and gait analysis recommended.



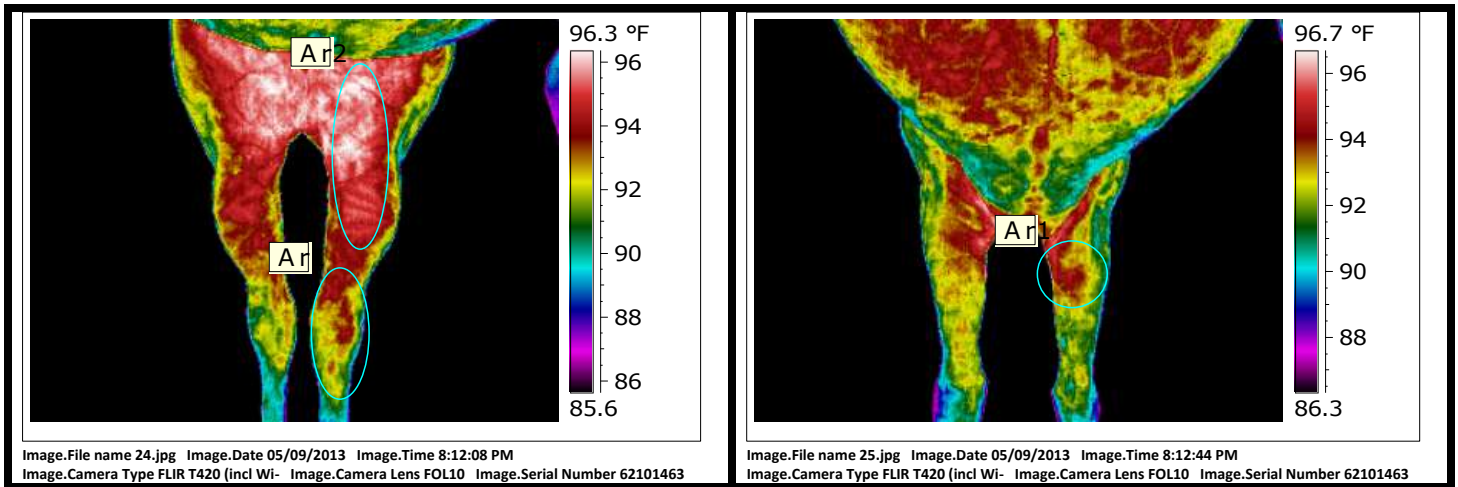
PATIENT: Zippo My Lady

THERMOGRAPHY DATE: September 5, 2013

IMAGING TIME: 7:50pm



Uneven heat/pressure seen in the left front foot which may be due to hoof imbalances or uneven limb loading. Increased heat both hind pasterns likely due to inflammation/infection. Decreased heat in the left hind fetlock may be due to artifact or uneven limb loading or circulatory blockage.



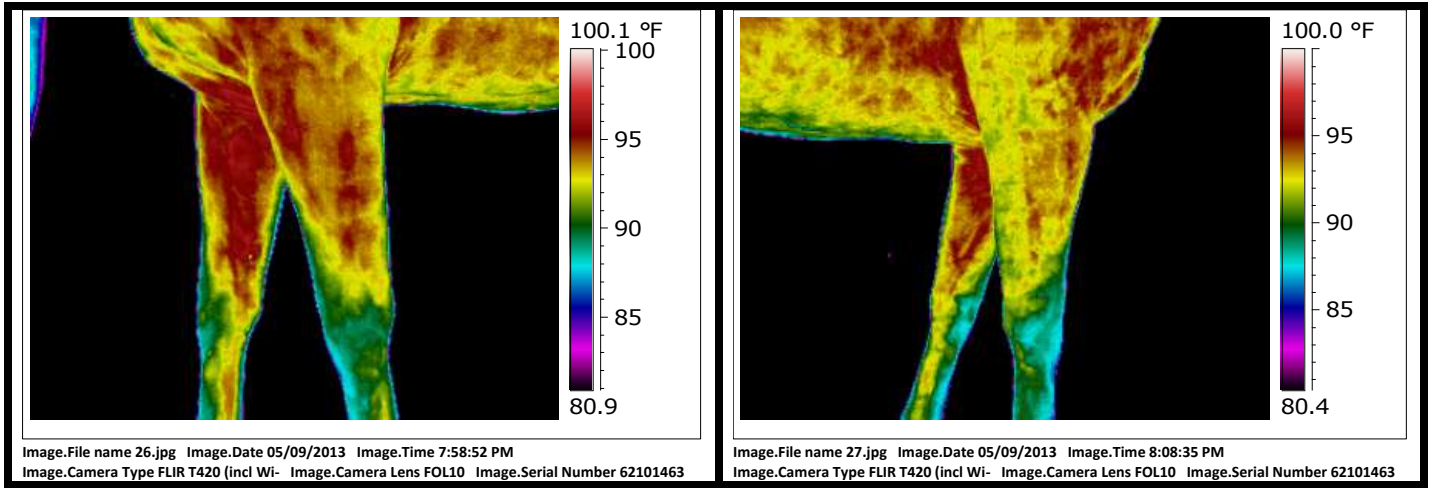
Asymmetry seen in the hock, medial thigh and forearm. Heat greater in the left hock/medial thigh and right forearm. This may be due to primary inflammation or off-loading of other limb. Palpation recommended as well as gait analysis and possible flexion testing of the left hock.



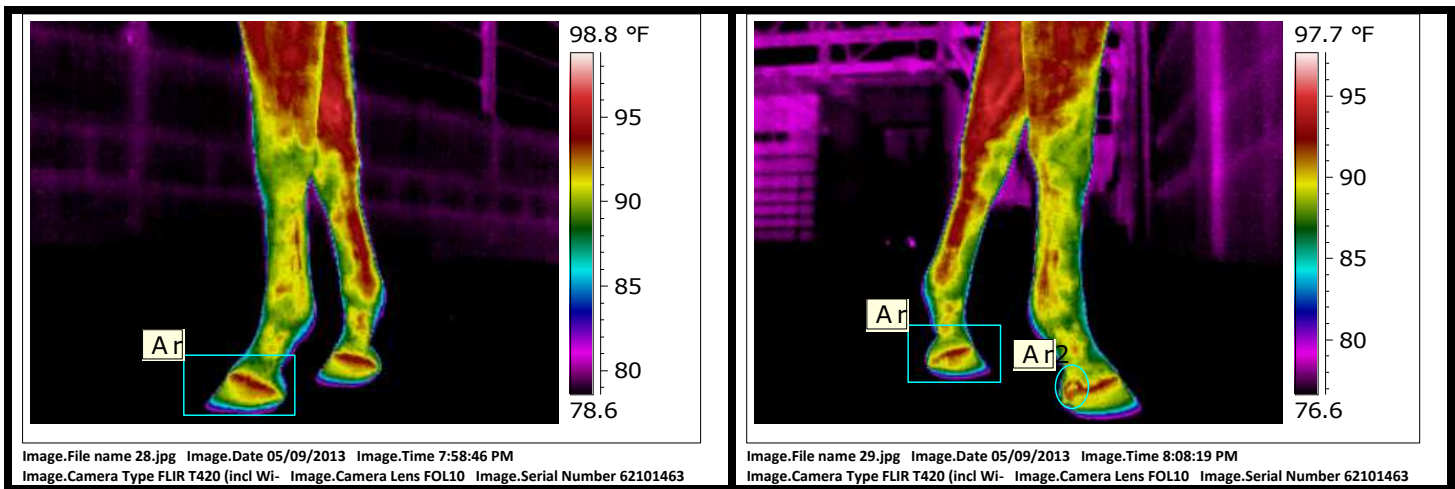
PATIENT: Zippo My Lady

THERMOGRAPHY DATE: September 5, 2013

IMAGING TIME: 7:50pm



NSF: No Significant Findings



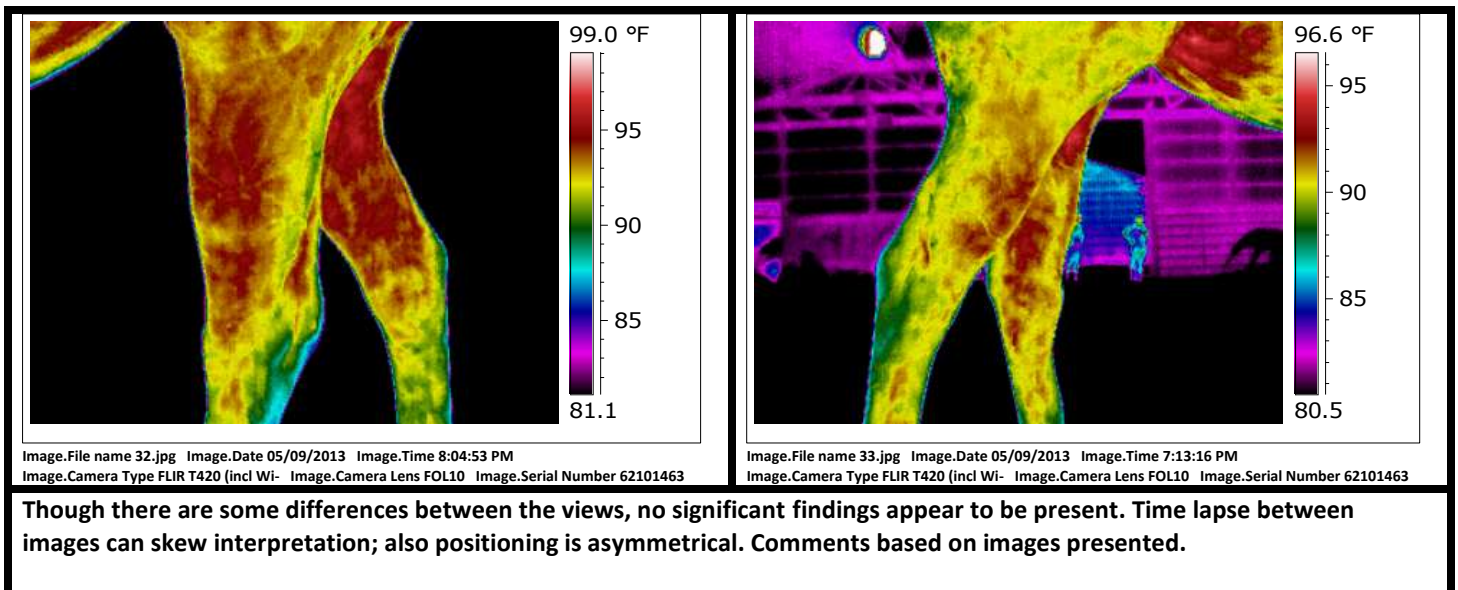
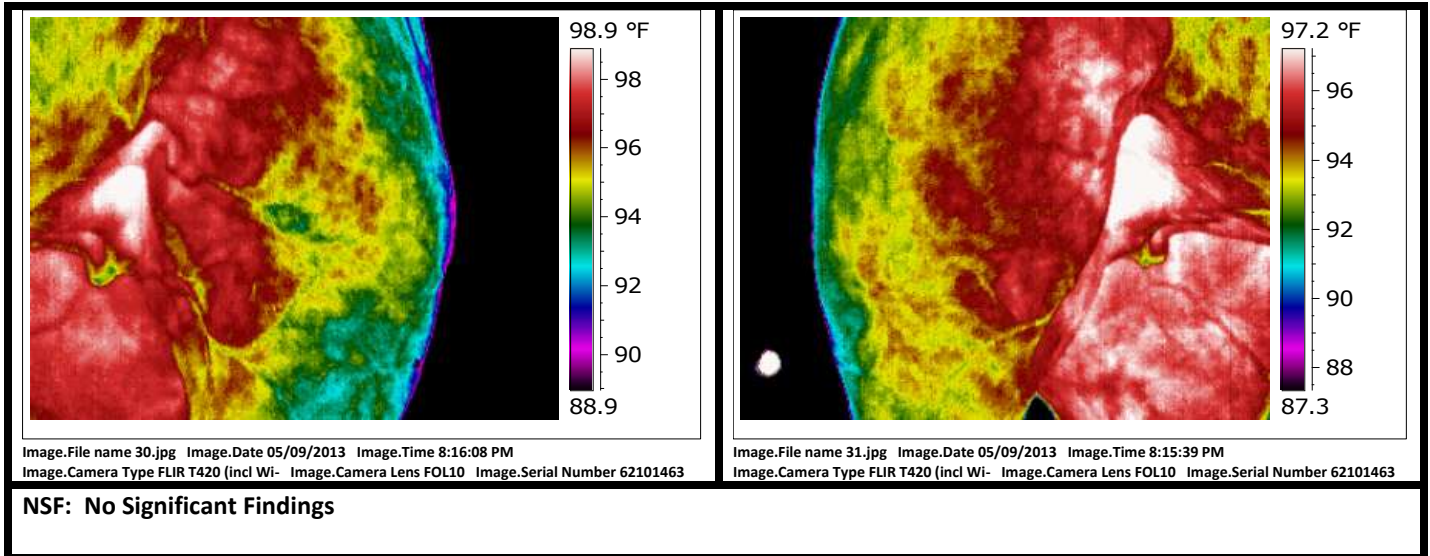
Increased heat and uneven pressure seen in left front foot. Right front foot shoes hoof defect seen in digital image. Uneven limb loading, hoof imbalances or inflammation/infection may be present. Thorough visual examination, hoof tester evaluation and postural analysis recommended.



PATIENT: Zippo My Lady

THERMOGRAPHY DATE: September 5, 2013

IMAGING TIME: 7:50pm

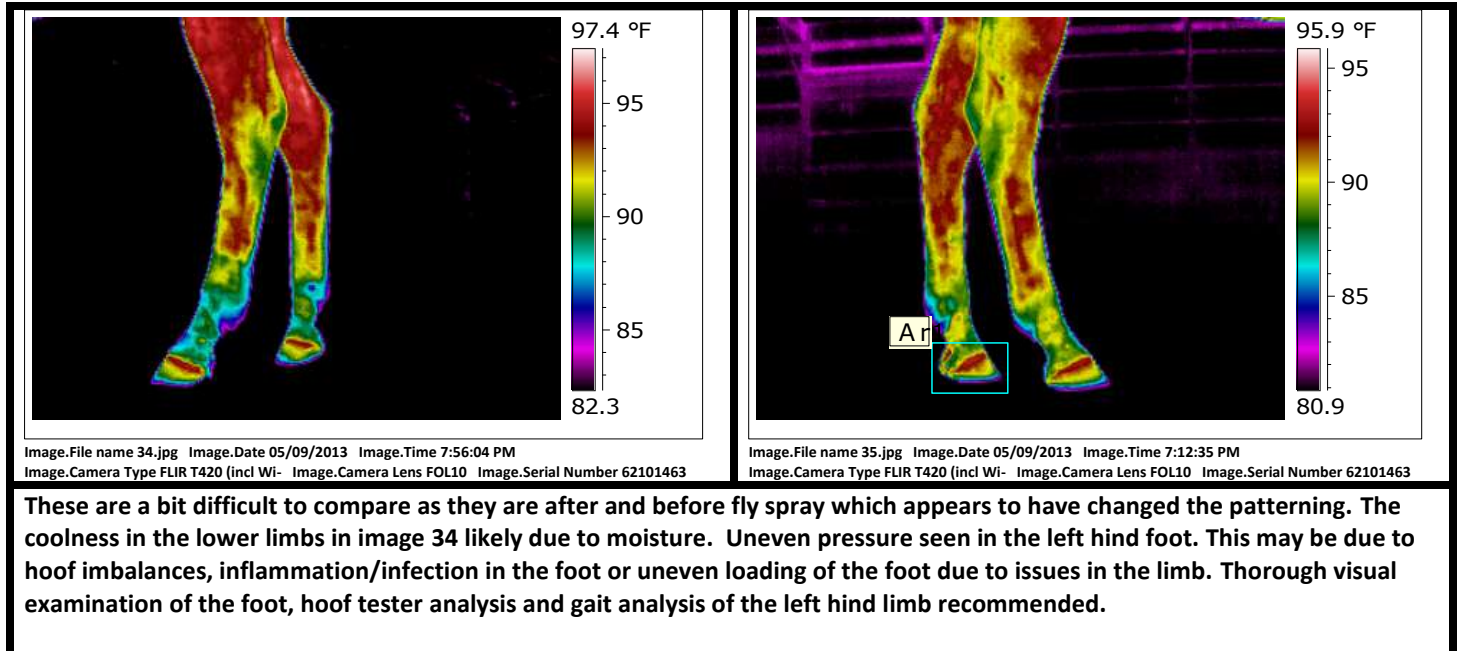




PATIENT: Zippo My Lady

THERMOGRAPHY DATE: September 5, 2013

IMAGING TIME: 7:50pm

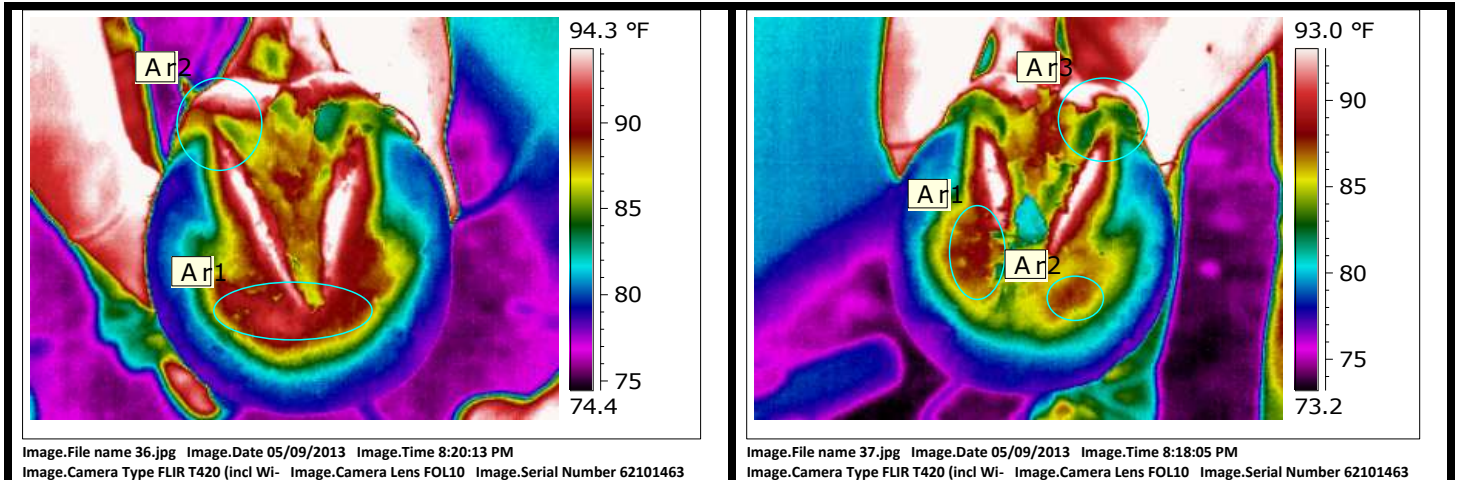




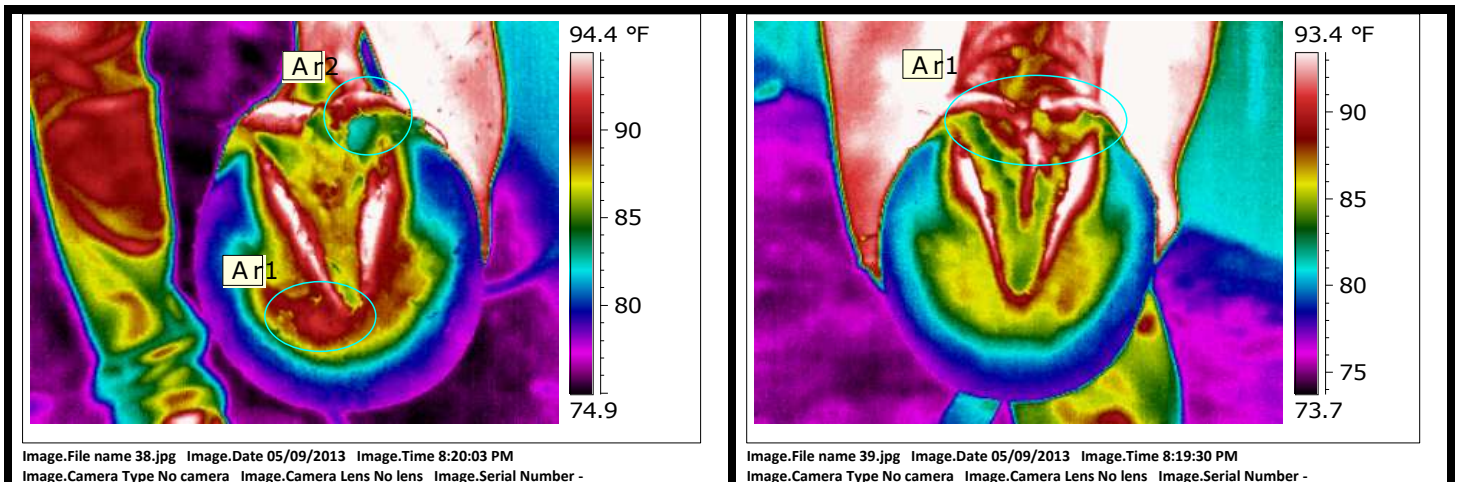
PATIENT: Zippo My Lady

THERMOGRAPHY DATE: September 5, 2013

IMAGING TIME: 7:50pm



There is a bit of wall and bar flare and uneven heel pressure. Increased heat/pressure seen in LF at the toe, greatest at the lateral toe quarter and in the RF at the lateral quarter. Increased heat in the frog sulci may represent infection. There may be uneven loading of the limb causing the focal pressure or hoof imbalances. The digital images were difficult to evaluate. Thorough visual exam recommended.



Slight wall and bar flare seen both hind feet. LH has uneven heel pressure. Frog sulci have increased which may represent infection. LH has increased heat at the lateral toe quarter which may be due to uneven limb loading or hoof imbalances.



PATIENT: Zippo My Lady

THERMOGRAPHY DATE: September 5, 2013

IMAGING TIME: 7:50pm

SUMMARY AND RECOMMENDATIONS: Zippo looks like a nice mare and we appreciate the opportunity to evaluate her images to help her regain soundness.

The lapse between some images and application of fly spray creates some issues but there is still valuable information from the images submitted.

The outward scars along the withers are seen in the cool patterning of the images and extend beyond the white areas in the digital images.

There is increased heat in the left shoulder which is consistent in all images. Palpation, motion palpation, flexion testing and possible further diagnostics such as ultrasound based on exam findings. Muscular strain/inflammation of the shoulder, injury/fixation of the scapulothoracic junction and/or scapulohumeral joint may be present. Palpation, motion palpation and thorough veterinary chiropractic/osteopathic evaluation recommended.

There is asymmetry in the left gluteal muscles/left hip, left semitendinosus muscle which may be due to primary musculoskeletal inflammation, secondary to inflammation in the lower limb or due to off-loading of other limb. Palpation, postural analysis and gait analysis recommended for further evaluation.

There is increased heat in the thoracolumbar spine and paraspinal muscles. Palpation and chiropractic evaluation recommended checking for inflammation and fixations/rotation of the vertebrae.

There is increased heat and uneven pressure in the left front foot which may be due to uneven limb loading from issues in the upper limb or hoof imbalances. Thorough visual examination of the foot and postural analysis of the left front limb recommended. Slight increased heat seen medial right forelimb. Palpation recommended ruling out inflammation.

Increased heat in both hind posterior pasterns likely due to inflammation/infection in the soft tissue based on digital images and history given. Increased heat left hock and medial thigh. This may be due to primary musculoskeletal inflammation or off-loading of other limb. Gait and postural analysis along with palpation and possible flexion testing recommended. There is increased heat/uneven pressure in the left hind foot which may be due to uneven limb loading, or hoof imbalances, or inflammation or infection in the foot. Thorough visual examination of the foot and hoof tester evaluation recommended along with the above for analyzing the limb.

Mild flare and hoof imbalances are seen in the thermal images of the feet. All frog sulci have increased heat which may represent infection – probing of the area recommended. This extends into the heel area in some views. The increased heat in the lateral toe quarters of the left front and left hind feet may be due to inflammation/infection or uneven loading of the foot either from imbalances of the foot and/or



Phone: 204-332-1333
Email: equine_resources@yahoo.ca
Web: www.equineresources.webs.com
www.equineir.com

PATIENT: Zippo My Lady

THERMOGRAPHY DATE: September 5, 2013

IMAGING TIME: 7:50pm

uneven loading of the limb due to injury or pain. Thorough visual examination of the feet, hoof tester evaluation and postural analysis recommended for further work-up.

Thank You!

Reviewing Veterinarian: Debra K Tibbitts, DVM ,CVCP, EDO, CVA, CIT

