



Equine BodyWorks USA

Revealing Affliction. Reducing Discomfort. Improving Movement & Performance.™

Saddle Fit Thermal Imaging Report McKiernan



*Thermal Imaging completed by
a Certified Thermographer
Authorized with the EquineIR™
Network.*



*Interpretative results
completed by Licensed
Veterinarians in contract with
Integrated Equine Infrared.*



Equine BodyWorks Infrared Thermal Imaging Services

2975 W. Hidden Lake Road, Mequon WI 53092

PH: 414-852-8621

FX: 262-241-2401



WEB: www.EquineBodyWorksUSA.com
EMAIL: becky@equinebodyworksusa.com



PATIENT: McKiernan **THERMOGRAPHY DATE:** 01.28.14 **TIME:** 11:15 AM

January 31, 2014

Dr. Lisa Borzynski
S103 W38296 County Highway NN
Eagle, WI 53119

Dear Dr. Borzynski:

Equine BodyWorks LLC was recently requested to perform a thermal imaging Saddle-Fit scan of: **McKiernan**

The following photo report was completed by your EquineIR™ Certified Thermographer and all interpretative results were channeled through interpretir.com and subsequently formulated and input by a licensed veterinary team member with Integrated Equine Infrared.

The interpretation is intended to aid your state-licensed veterinarian in providing a diagnostic or treatment protocol, if any. All follow-up testing and treatments, if any, should be conducted and administered by your primary veterinarian. The interpretation provided is based solely on the conditions at the time of survey and the thermal images included in this report. Thermography is a diagnostic tool that measures heat emitted from the surface of the patient. The thermal imaging camera converts infrared energy into a visible image. Emitted heat is related to circulation; as such, the thermal camera can help detect areas of inflammation as well as decreased circulation. Thermal symmetry is key, so we compare one anatomic area with the same area on the other side. The EquineIR™ report is prepared in this manner. It should be understood that correct patient preparation and environment are vital to a successful survey. Your EquineIR™ technician is also a Certified Infrared Thermographer and has been trained in the proper use and the proven techniques of thermal imaging as it is used with horses. However there are certain situations which may reduce the quality of the survey including the improper preparation of the horse prior to technician's arrival. The interpreting veterinarians who review the imagery base their findings and recommendations on information provided, so it is critical that proper care be taken in the preparation process to ensure success.

Thermal imaging is a physiologic modality and should not be relied upon as the sole diagnostic tool. While this report relates to a saddle fit assessment, to the extent issues relating to horse wellness are identified herein, a complete clinical examination by your licensed veterinarian is always recommended for the best diagnosis and follow-up treatment. This Report is not a definitive diagnosis of any illness or disease. It is intended for use only by licensed veterinary professionals to evaluate patient health, diagnose medical conditions, and provide treatment. It is not to be used by individuals for self-diagnosis or self-evaluation, nor for the diagnosis or evaluation of other non-qualified personnel. This report does not replace, nor is it intended to replace a complete clinical evaluation by your licensed veterinarian. Under no circumstances will EquineIR™, Integrated Equine Infrared or its affiliates be held responsible for illness, injury, or death to the patient as a result of the information contained herein. This report does not replace, nor is it intended to replace a complete clinical evaluation.

Your EquineIR™ Technician looks forward to working with you in the future. If you would like to set up an ongoing maintenance imaging program for your horse(s), we can arrange this at discounted rates along with multiple horse discounts. Please call our office with any questions as we would love to assist you in your success.

Sincerely,

Rebecca Tenges

Certified Equine Thermographer
Certified Infrared Thermographer
Equine BodyWorks LLC

PATIENT: McKiernan **THERMOGRAPHY DATE:** 01.28.14 **TIME:** 11:15 AM

EQUINE CLIENT INFORMATION

CLIENT NAME: Dr. Lisa Borzynski
MAILING ADDRESS: S103 W38296 County Highway NN, Eagle, WI 53119
CLIENT EMAIL: drborzy@aol.com
CLIENT PHONE: 763.370.2445

HORSE AGE: 10
HORSE BREED: Irish Sport
HORSE PRIMARY USE: Eventing & Hunter

SURVEY INFORMATION

THERMOGRAPHER: Rebecca Tenges
INFRARED CAMERA MODEL: FLIR T420 **CAMERA SERIAL NUMBER:** 62102950
NUMBER OF THERMAL IMAGES SUBMITTED: 8

WEATHER: Clear, Frigid, Windy. Imaging done in closed barn **APPROXIMATE TEMPERATURE:** 52 °F **IMAGING LOCATION:** Barn aisle

EXERCISED: Client rode **HOW LONG:** 12-15 minutes **WHEN:** SaddleFit done after Full Imaging Scan completed

FLYSPRAY OR LINIMENTS APPLIED WITHIN 24 HOURS: No

REASON FOR SCAN or HISTORY RECEIVED: To assess fit of saddle. McKiernan has grown approximately two inches and gained about 200 pounds over the last two years. Dr Borzynski wants to assess fit issues, if any.

TYPE OF SADDLE: Dressage **BRAND:** Passier
SERIAL NUMBER: Not Noted **COLOR:** Black **SIZE:** Not Noted **FLOCKING:** Wool **TYPE OF SADDLE PAD:** Mattes

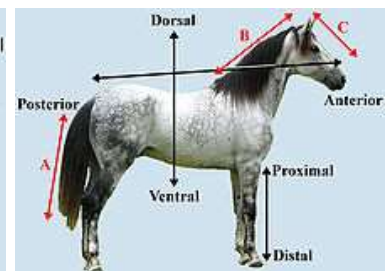
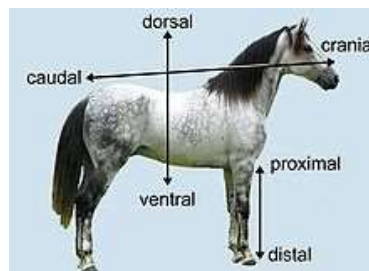
SADDLE-FIT INFORMATION: Thermography identifies areas of increased or decreased circulation or perfusion. As such, pressure points or hollow areas from ill-fitting saddles, pressure from uneven riders, and wither or back problems in horses, may be positively identified. However, thermal imaging is not a replacement for a complete veterinary physical examination, or a saddle-fitting evaluation from a Certified Master Saddler.

INTERPRETATION INFORMATION (Completed by Veterinarian)

INTERPRETATION TYPE: Saddle Fit Evaluation

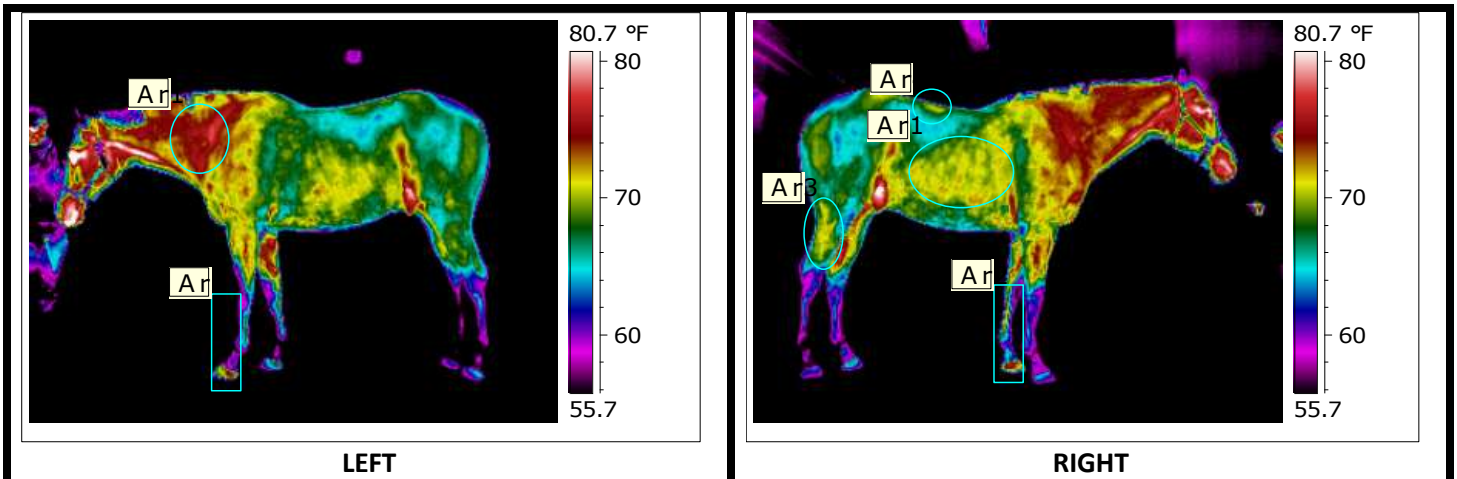
DATE OF INTERPRETATION: 1/31/2014

REVIEWING VETERINARIAN: Dr. Debra K Tibbitts

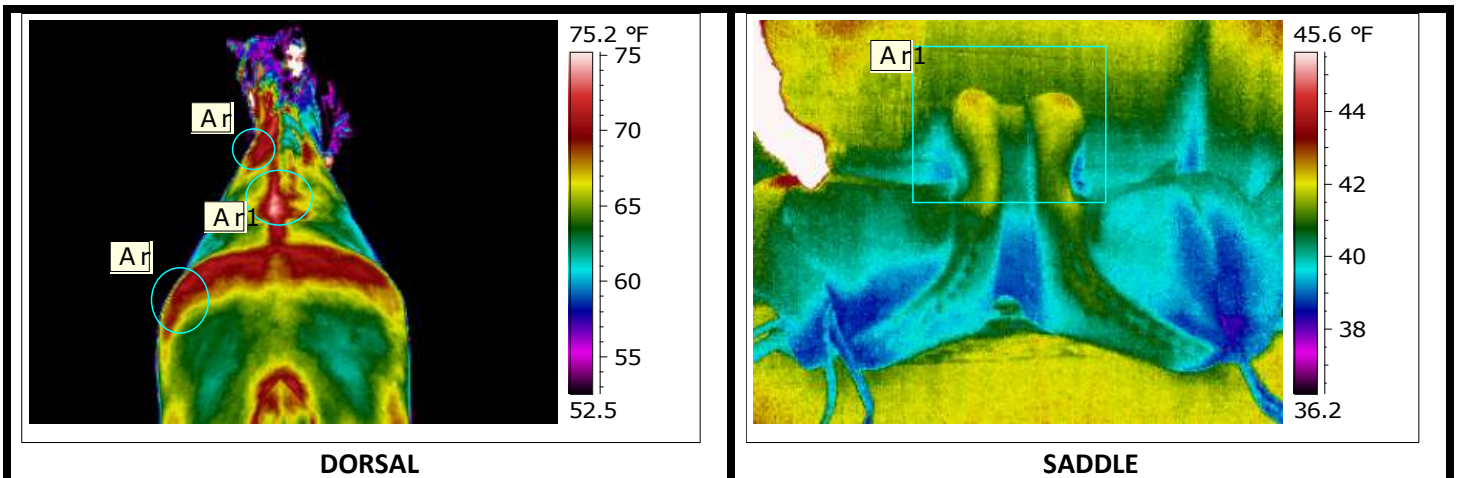


PATIENT: McKiernan THERMOGRAPHY DATE: 01.28.14 TIME: 11:15 AM

BEFORE EXERCISE



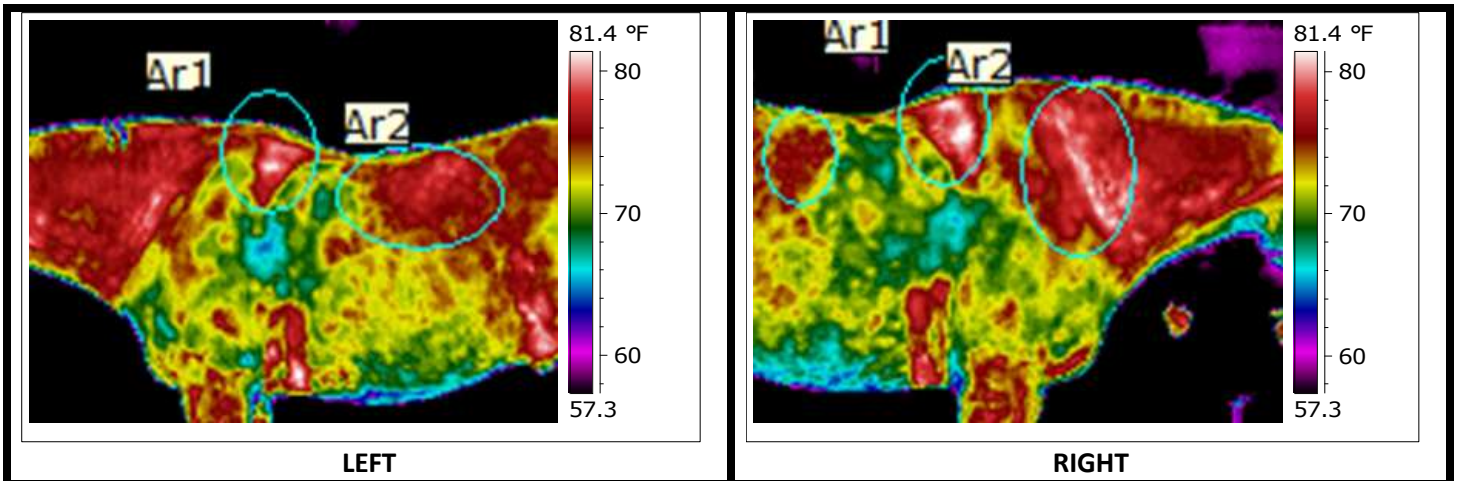
Some asymmetry seen on lateral views. There is increased heat in the left front foot and along the soft tissue of the lower limb. There is increased heat along the neck, particularly at the shoulder tie-in, greater on the left. The right gaskin has greater heat than the left indicating possible primary inflammation or muscle imbalance. Further details are included in the evaluation of the full scan. There is greater heat along the right rib area indicating muscular imbalances. There is also an area of increased heat on the right at the thoracolumbar spine which may be due to chiropractic lesions or saddle fit issues.



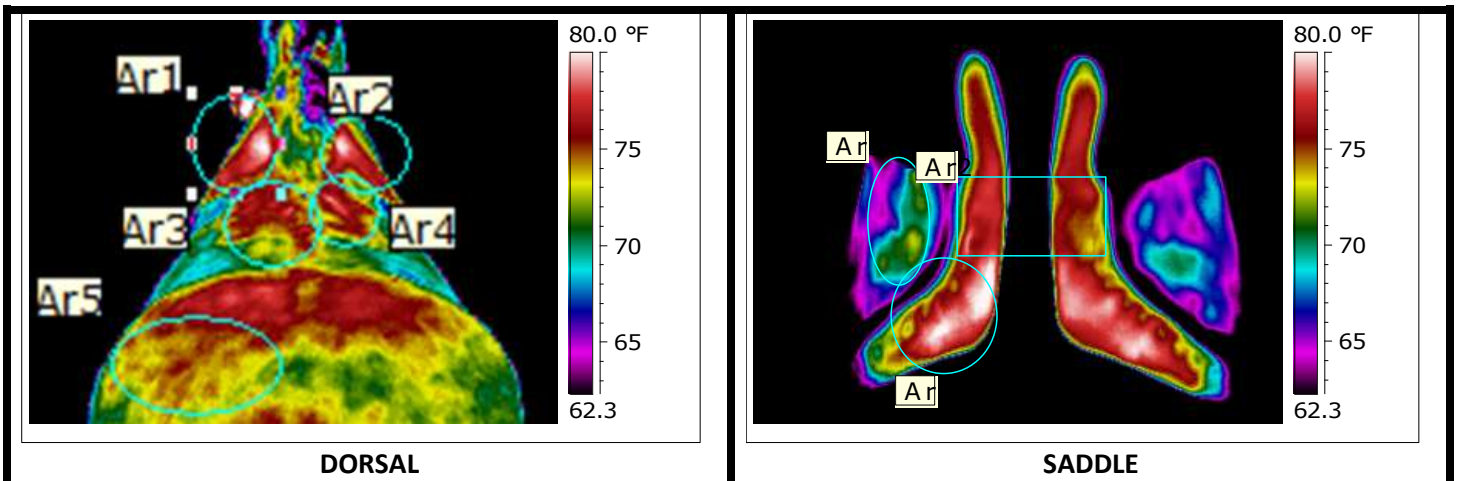
Increased heat withers and thoracolumbar spine with extension into the right paraspinal area. Increased heat left withers/shoulder. Right side of withers obscured by mane. Chiropractic lesions and/or saddle fit issues likely. Palpation and saddle fit analysis recommended. Increased heat left gluteals. The saddle shows uneven pressure/flocking of the rear part of the panels. The gullet channel seems to narrow (dovetail) at the rear. The sweat flap shows heat transference from person's hand.

PATIENT: McKiernan THERMOGRAPHY DATE: 01.28.14 TIME: 11:15 AM

AFTER EXERCISE



Increased heat at the withers and shoulder, greater on the right. There is also increased heat along the paraspinal muscles and ribs both sides, greater on the left indicating uneven pressure from the saddle or imbalances in the horse or rider.



There is increased heat at the withers and thoracolumbar spine, greater on the left. Also some asymmetry in the gluteal muscles, greater on the left. The saddle shows uneven pressure all along the panels as well as the flaps. Pressure appears greater on the left indicating uneven contact. The rear of the panels also appears to have limited contact creating increased pressure.



PATIENT: McKiernan **THERMOGRAPHY DATE:** 01.28.14 **TIME:** 11:15 AM

SUMMARY AND RECOMMENDATIONS: This saddle does not fit McKiernan. There is increased pressure at the withers indicating the saddle is too narrow. It also appears to be placed a bit too far forward. The rear of the panels has limited contact creating increased pressure and indicating the channel is too narrow and the panels are perched and/or flocking is uneven. Bridging is also present creating increased pressure at the front and rear of the panels and is another indication of a too narrow saddle. The uneven pressure along the front of the panels may indicate uneven flocking or uneven shoulder development. The uneven pressure in the flaps may indicate horse or rider imbalances.

McKieran needs a different saddle, one which is wider and conforms better to his conformation. As McKieran is brought further into work and his body changes it would be easier to make adjustments with an Adapatree saddle (www.saddlefit4life.com). More information about saddle fit can also be found at www.Schleese.com.

A full veterinary chiropractic evaluation is also highly recommended to further evaluate the inflammation seen in the spine.

Thank You!

Reviewing Veterinarian: Debra K Tibbitts, DVM, CVCP, EDO, CVA, CIT

